

Managing DME With Subthreshold Laser

In many cases, laser treatment offers myriad advantages and few downsides.

BY LIHTEH WU, MD



The treatment of choice for diabetic macular edema (DME) is anti-VEGF therapy which has largely superseded macular laser photocoagulation (MLP). However, not all patients respond equally to this therapy, and not all patients can afford it. At the same time, macular laser therapies have evolved from destructive thermal techniques to subthreshold ones that are tissue-sparing and non-thermal, such as Lumibird Medical's SubLiminal® Treatment mode (Figure 1A and B). Thus, there are certain instances where MLP remains a useful tool, such as in eyes with non-center-involved DME, in center-involved DME with good visual acuity, or in center-involved DME with a central macular thickness (CMT) of $\leq 400 \mu\text{m}$.

Most cases of non-center-involved DME can be managed by observation. However, in cases where patients are non-compliant, have difficulty traveling to doctor appointments, or live in areas with limited resources, MLP may be an option. Case 1 (described on the next page) illustrates this scenario.

CENTER-INVOLVED DME WITH GOOD VISUAL ACUITY ($\geq 20/25$): PROTOCOL V OF THE DRCR NETWORK

The Diabetic Retinopathy Clinical Research (DRCR) Protocol V concluded that in eyes

with center-involved DME and a good baseline visual acuity ($\geq 20/25$), initial treatment with MLP yields equivalent visual acuity outcomes to initial treatment with intravitreal aflibercept (Eylea, Regeneron) or observation.¹ However, MLP was associated with significant cost-savings relative to anti-VEGF therapy or observation.²

In the Protocol V study, patients were randomized to initial treatment with aflibercept injection, conventional MLP, or observation. If the visual acuity of patients in either the observation group or the MLP treatment group decreased from baseline, they were rescued with aflibercept. Of the 236 eyes assigned to observation, 80 (34%) received aflibercept within the 2-year study period, and in the laser photocoagulation group, aflibercept was initiated in 25% (60/240).¹ The cumulative probability of receiving aflibercept by 2 years was 26% in the MLP group and 36% in the observation group.¹

After 2 years of follow-up, the mean visual acuity was 20/20 in each group. Furthermore, the investigators determined that the percentage of patients with a greater than 5-letter decrease in visual acuity at 2 years was not statistically significantly different between the groups initially managed with aflibercept (16%), laser photocoagulation (17%), or observation (19%).¹

In a follow-up report, the investigators calculated the total per-person cost of each

approach over 10 years (in US dollars), including the cost of clinic visits, diagnostic testing, study interventions such as injection and laser, and additional interventions and complications over the 2-year period.² Because the study followed patients for only 2 years, the researchers extrapolated data for years 3 to 10, assuming that each patient would attend three clinic visits, undergo three OCT scans, and receive 0.5 injections per year in all groups. In the aflibercept-first group, the cost was almost \$30 billion. MLP, at just 50% of the cost of aflibercept, was the most economical intervention, even better than the observation-first approach. Moreover, a sensitivity analysis revealed that the cost of treating DME is largely driven by the cost of aflibercept.

EFFICACY OF THE SUBTHRESHOLD LASER FOR TREATING DME

Over the past decade, numerous studies have validated the safety and efficacy of the subthreshold laser for treating DME. The data suggest that the subthreshold laser achieves at least equivalent clinical outcomes as conventional MLP, but with less iatrogenic trauma to retinal tissue.

Mansouri et al reported that the best results of subthreshold laser application in eyes with DME are obtained when the CMT is $< 400 \mu\text{m}$.³ After 12 months, the eyes with a CMT of $< 400 \mu\text{m}$ ($n = 33$) experienced an average of

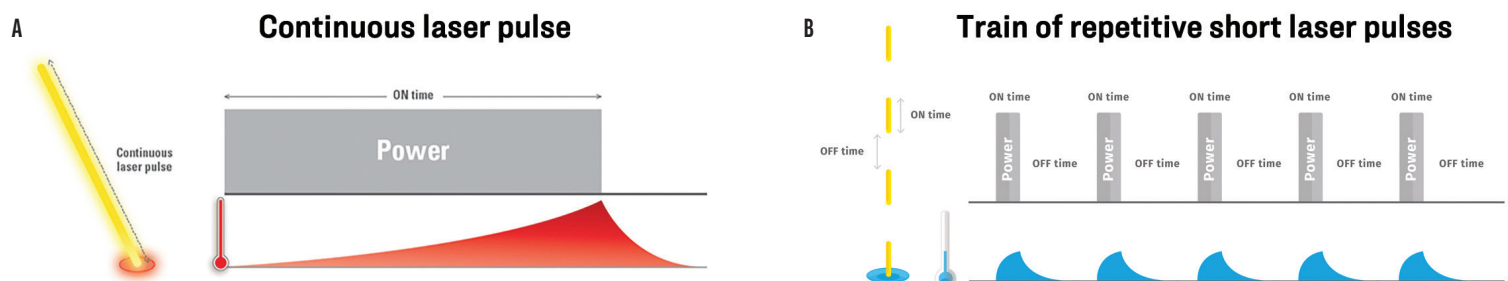


Figure 1. Thermal laser therapy (A) vs Lumibird Medical's subthreshold laser therapy (B).

Sponsored by  LUMIBIRD[®]
MEDICAL

CASE 1:

A 75-year-old man with a 33-year history of type 2 diabetes had a visual acuity of 20/40 in both eyes. He was noted to have non-center-involved DME OS. The patient lived far from the clinic and could not return regularly to get monitored. I decided to treat him with subthreshold laser therapy from Lumibird Medical. Four months after treatment, his left eye showed a complete resolution of the retinal thickening (Figure).

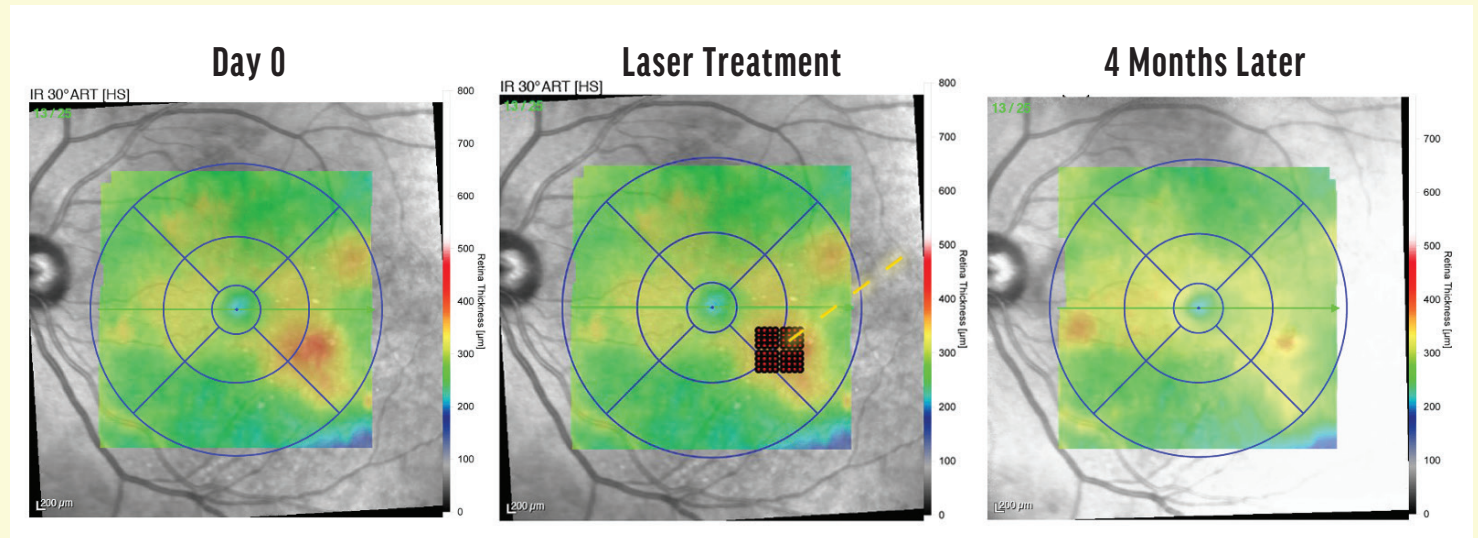


Figure. Subthreshold laser therapy on day 0 (left), the retinal area treated by laser (middle), and 4 months postoperatively (right).

a 55- μm reduction in CMT and a 0.2 logMAR gain in visual acuity; additionally, no patients required rescue therapy with anti-VEGF injections. By comparison, there was no change in CMT or visual acuity in eyes with a CMT of $> 400 \mu\text{m}$ ($n = 30$) by month 6. By month 12, all eyes had received rescue therapy with bevacizumab (Avastin, Genentech).³

More recently, a double-masked, randomized, multicenter, noninferiority study conducted in the UK compared the outcomes of the subthreshold laser versus standard MLP for treating DME in eyes with a CMT of $\leq 400 \mu\text{m}$.⁴ The mean change in BCVA at 24 months was the primary

outcome. At month 24, the mean change in BCVA from baseline was -2.43 ± 8.30 letters in the subthreshold laser group and -0.45 ± 6.72 letters in the MLP group. The subthreshold laser was deemed to be not only noninferior, but equivalent to MLP in efficacy. And, in a cost analysis, the investigators found no difference between the two treatments.⁴

A meta-analysis performed in 2016 of six randomized, controlled clinical trials that evaluated the efficacy of conventional MLP versus the subthreshold laser for treating DME showed that there was no difference in the resolution of DME between the two treatment regimens at 12 months after

treatment. The subthreshold laser delivered superior visual outcomes, suggesting that perhaps the subthreshold laser causes less iatrogenic macular damage, as evidenced by microperimetry.⁵

Other studies have similarly shown that the subthreshold laser may diminish the anti-VEGF treatment burden.⁶⁻⁸ In one meta-analysis, researchers reported that there were significantly fewer anti-VEGF injections in eyes that were treated with a combination of laser and intravitreal anti-VEGF injections versus anti-VEGF monotherapy.⁹

MECHANISM OF ACTION OF THE SUBTHRESHOLD LASER

Two studies published by Midena et al in Italy have demonstrated that changes in inflammatory and vaso-active biomarkers of the aqueous humor following the application of the subthreshold laser implicate activated microglia and Müller cells in the pathogenesis of DME. After treatment with the laser,

"MACULAR LASER THERAPY, AT JUST 50% OF THE COST OF AFLIBERCEPT, WAS THE MOST ECONOMICAL INTERVENTION, EVEN BETTER THAN THE OBSERVATION-FIRST APPROACH."

CASE 2:

A 67-year-old man with diabetes noted on screening presented with a visual acuity of 20/30 OD. He was diagnosed with center-involved DME in the right eye. I decided to treat the eye with subthreshold laser therapy from Lumibird Medical. Six months after treatment, the visual acuity of the patient improved to 20/20, and his eye showed a complete resolution of the retinal thickening (Figure).

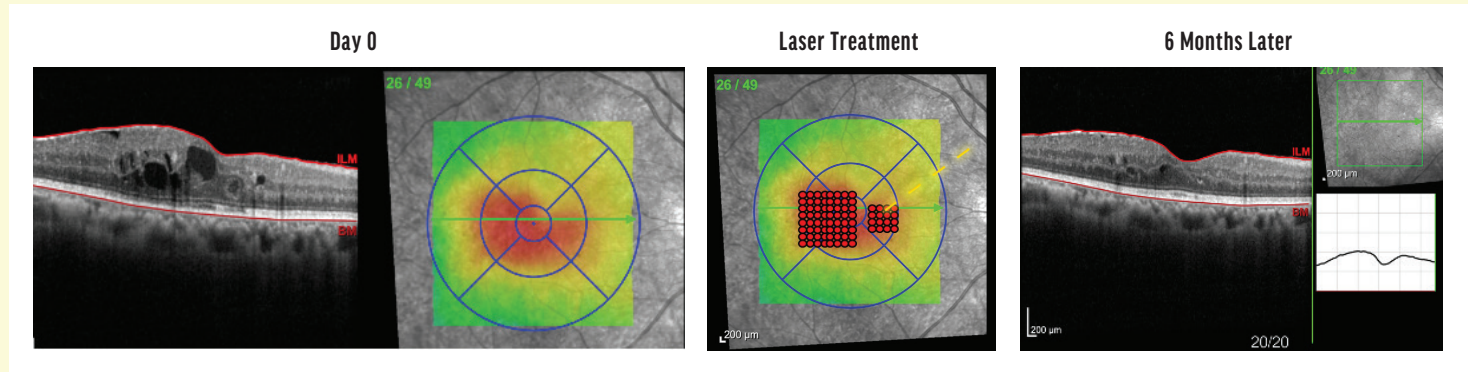


Figure. Subthreshold laser therapy showed on day 0 (left), during laser treatment (middle), and 6 months postoperatively (right).

inflammatory cytokines mainly produced from activated microglia were significantly reduced^{10,11} (see case 2).

SUMMARY

In select cases of non-central DME, center-involved DME with a good visual acuity, and center-involved DME with a CMT of $\leq 400 \mu\text{m}$, when patients are non-compliant, have difficulty traveling to doctor appointments, or live in areas with limited resources, MLP may be indicated for DME. Subthreshold laser photocoagulation is equivalent to conventional MLP in terms of efficacy. I recommend using the subthreshold laser if available in lieu of MLP, since it does not burn the retina, and the studies described herein have

indicated that it may deactivate microglial cells and Müller cells. ■

1. Glassman AR, Baker CW, Beaulieu WT, et al. Assessment of the DRCR Retina Network approach to management with initial observation for eyes with center-involved diabetic macular edema and good visual acuity. *JAMA Ophthalmol.* 2020;138(4):341-349.
2. Hutton DW, Glassman AR, Stein JD, et al. Costs of managing diabetic macular edema with good visual acuity with aflibercept, laser, or observation: DRCR Retina Network Protocol V. *Am J Ophthalmol.* 2019;321:1880-1894.
3. Mansouri A, Sampat KM, Malik KJ, et al. Efficacy of subthreshold micropulse laser in the treatment of diabetic macular edema is influenced by pre-treatment central foveal thickness. *Eye (Lond).* 2014;28(12):1418-1424.
4. Lois N, Campbell C, Waugh N, et al; DIAMONDS Study Group. Diabetic macular edema and diode subthreshold micropulse laser: a randomized double-masked noninferiority clinical trial. *Ophthalmology.* 2023;130(1):14-27.
5. Chen G, Tzekov R, Li W, et al. Subthreshold micropulse diode laser versus conventional laser photocoagulation for diabetic macular edema: a meta-analysis of randomized controlled trials. *Retina.* 2016;36(11):2059-2065.
6. Moisseiev E, Abbassi S, Thinder S, et al. Subthreshold micropulse laser reduces anti-VEGF injection burden in patients with diabetic macular edema. *Eur J Ophthalmol.* 2018;28(1):68-73.
7. Abouhoussein MA, Gomaa AR. Aflibercept plus micropulse laser versus aflibercept monotherapy for diabetic macular edema: 1-year results of a randomized clinical trial. *Int Ophthalmol.* 2020;40:1147-1154.
8. Kanar HS, Arsan A, Altun A, et al. Can subthreshold micropulse yellow laser treatment change the anti-vascular endothelial growth factor algorithm in diabetic macular edema? A randomized clinical trial. *Indian J Ophthalmol.* 2020;68(1):145-151.

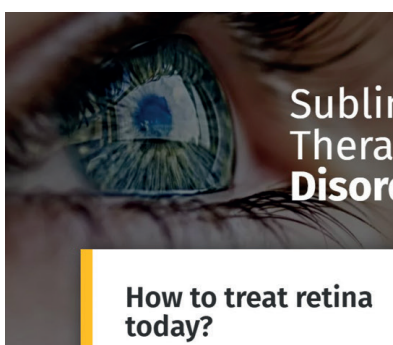
9. Wijweera C, Ni J, Petocz P, et al. Efficacy of anti-VEGF monotherapy versus anti-VEGF therapy with subthreshold micropulse laser (SML) in the management of diabetic macular oedema (DMO): a systematic review and meta-analysis. *Graefes Arch Clin Exp Ophthalmol.* 2024;262(9):2733-2749.

10. Midena E, Micera A, Frizziero L, et al. Sub-threshold micropulse laser treatment reduces inflammatory biomarkers in aqueous humour of diabetic patients with macular edema. *Sci Rep.* 2019;9(1):10034.


11. Midena E, Bini S, Martini F. Changes of aqueous humor Müller cells' biomarkers in human patients affected by diabetic macular edema after subthreshold micropulse laser treatment. *Retina.* 2020;40(1):126-134.

LIHTEH WU, MD

- Consulting Surgeon with the Asociados de Macula Vitreo y Retina de Costa Rica, San José, Costa Rica
- Founding member of the Pan American Collaborative Retina Study (PACORES) Group
- LW65@cornell.edu
- Financial disclosures: Lecture fees (Apellis Pharmaceuticals, Astellas Pharma, Bayer, Genentech/Roche, Lumibird Medical); Consultant (Bayer, Genentech/Roche)



Subliminal Laser Therapy for Retinal Disorders



LEARN MORE ABOUT SUBLIMINAL SUBTHRESHOLD LASER THERAPY

How to treat retina today?

